Poster # S063

Protection of blue light induced retinal degeneration by the free radical scavenger Phenyl-N-tert-butylnitrone and a serotonin receptor 5-HT1A agonist in rats

S Grillo-Antonelli, N Cimbolini, H Dubos, L Feraille, P Margaron, P Elena. *Iris Pharma La Gaude France*

A GLOBAL SERVICE PROVIDER OF PRECLINICAL AND CLINICAL RESEARCH IN OPHTHALMOLOGY

Introduction

Retinal degenerations are among the major causes of severe visual impairment in industrialized countries. Age-related macular degeneration (AMD) is the most prevalent, but other inherited retinal degenerations, including retinitis pigmentosa (RP), also contribute to visual loss. Apoptosis of photoreceptors and RPE (Retinal Pigment Epithelium) is the final cell death pathway in RP and AMD (1).

Exposure to excessive levels of light especially from short wavelengths induces photoreceptor apoptosis (2) and has previously been used as a model for the study of retinal degeneration. The mechanism by wich light induces retinal degeneration is not completely understood. Rhodopsin is essential for light induced retinal degeneration, indicating that the signal flow through phototransduction cascade is necessary to mediate the damaging effect of light (3).

A diverse range of agents has been used to prevent photoreceptor apoptosis in the light induced retinal degeneration. These include calcium channel blockers (4), antioxidant such as dimethylthiourea (5), free radical spin trapping agents such as phenyl-N-tert-butylnitrone (PBN) (6), caspase inhibitors (7), drugs that upregulate endogenous neurotrophic factors such as alpha 2 agonist (8) and more recently the serotonin receptor 5-HT1A agonist (9).

The aim of this study was to compare efficacy of an anti-oxidant, PBN, and a serotonin receptor agosnist, 8-Hydroxy-2-(dipropylamino)tetralin hydrobromide (8OHDPAT).

Material and method

Animals and treatment

Twenty four male Spague Dawley rats (350-400g) were randomized in three groups. Rats of the first group received subcutaneous injection of 8OHDPAT, 500µg/kg (once a day, from two days before to two days after the light exposure), the second group was injected intraperitonally with PBN 50mg/kg four time during the day of exposure, rats of the third group were injected by NaCl 0,09%.

Animals were handled and cared for according to the ARVO Statement for the Use of Animals in Ophthalmic and Vision Research. Food and water were available ad libitum. Rats were kept under 12h light (50-100 lux) and 12h dark cycle.

Light Exposure

The rats were dark-adapted for 36 hours before being exposed for 6 hours to continuous blue fluorescent light (400-540 nm). After exposure, the rats were placed in dark room during 24 hours and then returned to normal cyclic light conditions.

Electroretinogram (ERG)

Scotopic ERG was recorded, using system RETI-animal® (Roland Consult) in both eyes after overnight dark adaptation. Standard flash ERGs were obtained using a single flash intensity of 3 cd.s/m^2 on dilated eyes, on days 7 and 14 after light exposure.

In vivo retinal imaging

SD-OCT imaging was performed with a SpectralisTM (Heidelberg Engineering). 14 days after the light damage, retina were observed for autofluorescence and infra red imaging. Blue laser autofluoresence was used to detect the natural fluorescence emitted by retinal pigment cells, infrared laser provided high resolution images of the retina.

Study Termination and Measurement of the ONL Thickness

After Day 14 animals were euthanized and enucleated, embedded in paraffin, Vertical sections (5 to 7 µm thick) were cut through the optic nerve and stained with hematoxylin/eosin, ONL thickness was measured every 500 µm from the optic nerve to the peripheral retina in vertical sections.

Results

Electroretinography

Blue light expure induced a 80% decrease of the a-wave (photoreceptor function) and b-wave (mixed response: photoreceptor and bipolar cell response) amplitudes in placebo group 7 and 14 days after the induction. A and b-wave response was signicatively higher in 8OHDPAT and PBN treated groups at both time-points. Both compounds induced almost the same recovery from the baseline response for a and b- waves: 77 and 84% of a-wave the baseline values 7 and 14 days after exposure and b-wave, 78 and 95%, 7 and 14 days after exposure respectively.

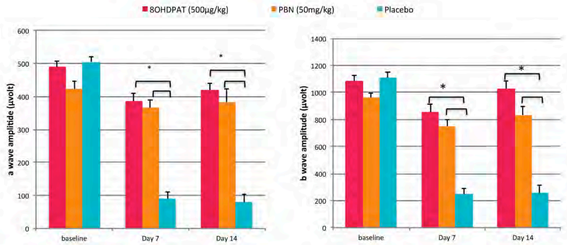

Statistical analysis

Result were expressed as mean +/- SEM. Data were compared using the nonparametric Mann-Whitney. * p < 0,05.

In vivo retinal imaging

Retina of rats treated with placebo showed large hyperfluorescent area typical of suffering RPE (a). These lesions are considerably reduced or even absent in 8 OHDPAT (c) and PBN treated rats (d). SD-OCT scans provided qualitative images of retinal layers with complete disappearance of ONL in most of placebo-treated rats (a) and preservation of retina integrity with 8OHDPAT (b) or PBN (c) treated rats.

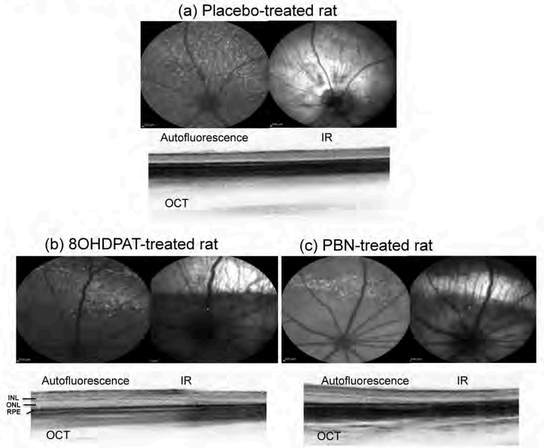

ONL thicknes

To assess whether the treatment to preserve photoreceptor structure, the ONL thickness was evaluated by histology 14 days after exposure. Photomicrographs showed massive degeneration, with many photoreceptor nuclei missing (B) compared to uninjured retina (A).

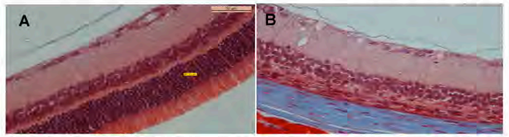

Hematoxylin/eosin labelled section of retina. Control retina (A) and light injured retina (B)

As seen with SD-OCT scan, 6h blue light exposure induced a loss of ONL thickness. Measurement of ONL thickness on vertical section (a) or Area Under the Curve (AUC) (mean+/- SEM per group) (b) shown that administration of 8OHDPAT or PBN induced a significant protection of ONL compared with vehicle groups.

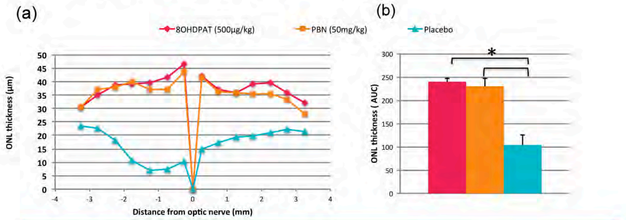

Conclusion

Significant protection of retina from light-induced degeneration was achieved with 8OHDPAT and PBN, which effectively rescued a-wave and b-wave amplitudes of ERG responses and preserved photoreceptor layer thickness.

The serotonin receptor 5-HT1A could be a valuable target for AMD and other retinal degenerative diseases.

References

1 - Chang GQ, Hao Y, Wong F. Apoptosis: final common pathway of photoreceptor death in rd, rds, and rhodopsin mutant mice. Neuron. 1993 Oct;11(4):595-605.
2 - Van Norren D, Schellekens P. Blue light hazard in rat. Vision Res. 1990;30(10):1517-20.
3 - Grimm C, Wenzel A, Williams T, Rol P, Hafezi F, Remé C. Rhodopsin-mediated blue-light damage to the rat retina: effect of photoreversal of bleaching. Invest Ophthalmol Vis Sci. 2001 Feb;42(2):497-505.
4 - Edward DP, Lam TT, Shahinfar S, Li J, Tso MO. Amelioration of light-induced retinal degeneration by a calcium overload blocker. Flunarizine. Arch Ophthalmol. 1991 Apr;109(4):554-62.
5 - Organisciak DT, Darrow RM, Jiang YI, Marak GE, Blanks JC. Protection by dimethylthiourea against retinal light damage in rats. Invest Ophthalmol Vis Sci. 1992 Apr;33(5):1599-609.
6 - Ranchon I, Chen S, Alvarez K, Anderson RE. Systemic administration of phenyl-N-tert-butylnitrone protects the retina from light damage. Invest Ophthalmol Vis Sci. 2001 May;42(6):1375-9.
7 - Liu C, Li Y, Peng M, Laties AM, Wen R.. Activation of caspase-3 in the retina of transgenic rats with the rhodopsin mutation s334ter during photoreceptor dégénération. J Neurosci. 1999 Jun 15;19(12):4778-85.
8 - Wen R, Cheng T, Li Y, Cao W, Steinberg RH.. Alpha 2-adrenergic agonists induce basic fibroblast growth factor expression in photoreceptors in vivo and ameliorate light damage. J Neurosci. 1996 Oct 1;16(19): 5986-92.
9 - Collier RJ, Patel Y, Martin EA, Dembinska O, Hellberg M, Krueger DS, Kapin MA, Romano C. Agonists at the serotonin receptor (5-HT(1A)) protect the retina from severe photo-oxidative stress. Invest Ophthalmol Vis Sci. 2011 Apr 4;52(5):2118-26.

Visit us on www.iris-pharma.com