

Anti-inflammatory effects of glucocorticoids on Endotoxin-Induced Uveitis (EIU) in rats: impact of the mode of administration.

Pierre-Paul Elena, Sophie Antonelli, Nicolas Cimbolini, H el ene Dubos, Laurence Feraille and Philippe Margaron. Iris Pharma, La Gaude, France

Program 6285
Poster D1145

Background

The model of Endotoxin-Induced Uveitis (EIU) in the rat is a useful animal model for human anterior uveitis (1). The systemic administration of lipopolysaccharides (LPS) results in an acute inflammatory response in the anterior and posterior segments of the eye with a breakdown of blood-ocular barrier and inflammatory cell infiltration. Clinical signs of EIU, including protein flare and cell in the aqueous humor, miosis and posterior synechiae, fibrin clots and hypopion, reflect the changes seen in the human disease. Exposure to LPS stimulates cellular inflammatory responses and releases of inflammatory mediators such as cytokines and chemokines (2), including interleukin-6 (IL-6) and interleukin-1 beta (IL-1 ).

Systemic corticosteroids are widely used for the management of posterior segment inflammation that requires treatment, particularly when it is associated with systemic disease or when bilateral ocular disease is present. However, when ocular inflammation is unilateral or is active in one eye only, local therapy has considerable advantages. In this regard, periocular injections of corticosteroid are a useful alternative to systemic medication.

This study examined the outcomes of glucocorticoids administered topically, systemically, or subconjunctivally on endotoxin-induced uveitis in rats.

Material and method

Animals, EIU Induction and Treatment

EIU was induced in male Lewis rats, weighing 180 to 200 g by footpad injection of 200  g of LPS that had been diluted in 0.1 mL of sterile water. Animals were then randomized in four groups. The first two groups received either a single intravenous dose of 2.5 mg/kg dexamethasone phosphate (immediately after LPS inoculation) or multiple instillations of 0.1% dexamethasone (1h before and 1h, 2h and 3h after induction). The third group received a single subconjunctival dose of 1 mg methylprednisolone. A non-treated induced group was used as control of induction.

Animals were handled and cared for according to the ARVO Statement for the Use of Animals in Ophthalmic and Vision Research.

Clinical Evaluation of EIU

Animals were examined with a slit lamp biomicroscope 24 hours later, corresponding to the peak severity for EIU. Clinical ocular inflammation was scored in each eye using a scale from 0 to 7 as follows: iris hyperemia and cell in the anterior chamber 0-2, (0 = no sign; 1 = mild ; 2 = severe) and flare, myosis and hypopion were scored 0 for no sign or 1 for presence. The maximum possible score was 7 (sum of the 5 parameter scores). (3)

Measurement of Infiltrating Cells and Protein Concentration in Aqueous Humor

At 24 hours after LPS injection, the rats were euthanatized and 10 l of the aqueous humor (AH) was collected immediately and thereafter diluted 10-fold in PBS. The total protein concentration in the aqueous humor samples was measured with the Bradford method and expressed in milligrams per milliliter.

Levels of IL-1  , IL-6, IL-12 in Aqueous Humor

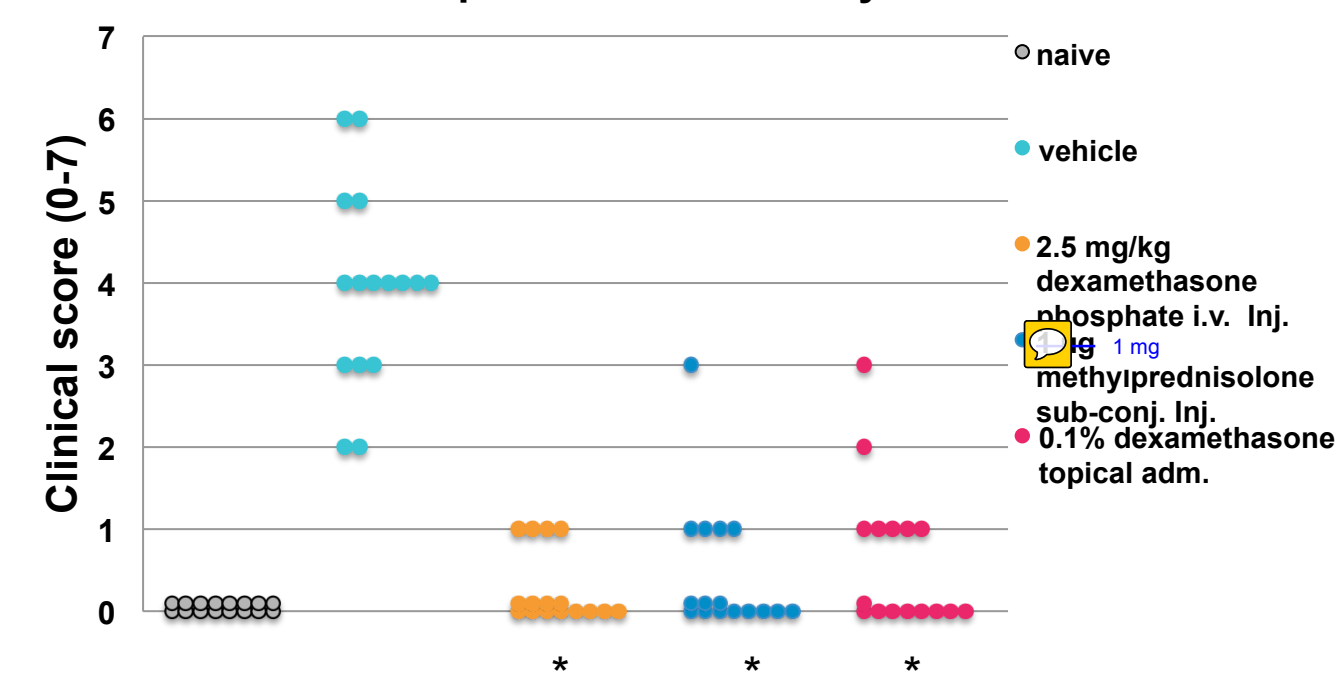
The aqueous humor samples were stored at -80 c until testing. The levels of cytokines were determined by the Luminex xMAP detection method using Procarta Immunoassay Kits as per the manufacturer's protocol. The results were expressed in picograms per milliliter.

Results

Clinical Evaluation

24h after LPS injection, untreated animals displayed clinical signs of uveitis, in contrast to the glucocorticoid treatments, which showed a similar diminution of the clinical signs, regardless of the route of administration. Intravenous dexamethasone phosphate administration (2.5 mg/kg), multiple instillations of 0.1% dexamethasone as well as sub-conjunctival administration of methylprednisolone significantly reduced the clinical score of uveitis from 3.9 (+/-0.3) for untreated group down to 0.3 (+/-0.1), 0.4 (+/-0.2) and 0.6 (+/-0.2). Control rats without any induction had no clinical signs of uveitis.

Figure 1 : Slit lamp evaluation of LPS induced uveitis in rat, 24h after induction. Dots represent individual eyes.



Statistical analysis

Result were expressed as mean +/- SEM. Data were compared using the nonparametric Mann-Whitney statistical test. * : p < 0,05.

Inflammatory Cells and Protein Concentration in Aqueous Humor

24 hours after LPS injection, inflammatory cells were found in the anterior segment. In the LPS group, the mean of inflammatory cells that infiltrated into the aqueous humor was 2644 cells/ l (+/-281). Rats treated with glucocorticoids showed a significant reduced count of inflammatory cells, 54 cells/ l (+/-12) were found with intravenous dexamethasone phosphate, 797 cells/ l (+/-147) with sub-conjunctival administration of methylprednisolone and 79 cells/ l (+/- 13) with multiple instillations of 0.1% dexamethasone. In the control group, no infiltrating cells were detected in the aqueous humor.

In the naive group, protein concentration in the aqueous humor was 4.3 mg/ml (+/-1.2) and was increased to 31.4 mg/ml (+/-3.4) with LPS injection. In the rats treated with glucocorticoids, protein concentration was reduced by 98% for intravenous dexamethasone phosphate, by 70% sub-conjunctival administration of methylprednisolone, by 97% for multiple instillations of 0.1% dexamethasone.

Figure 2 : Cell infiltration in rat aqueous humor 24h after LPS induction of uveitis.

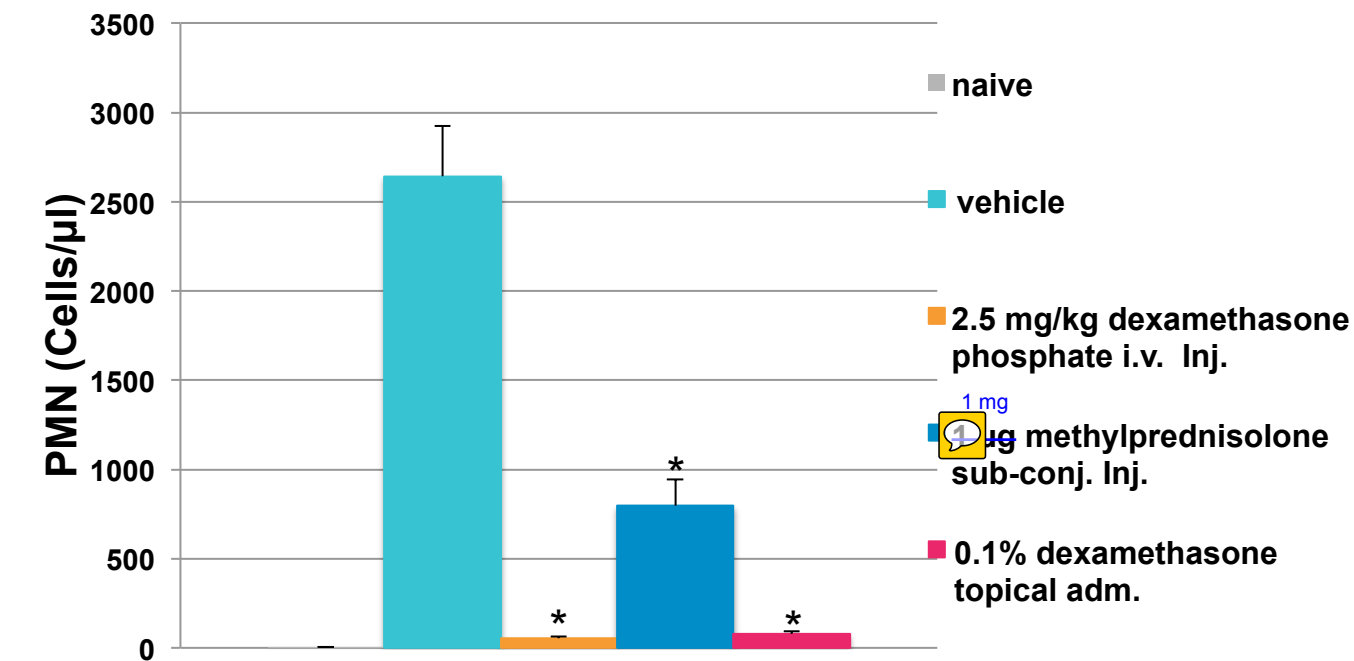
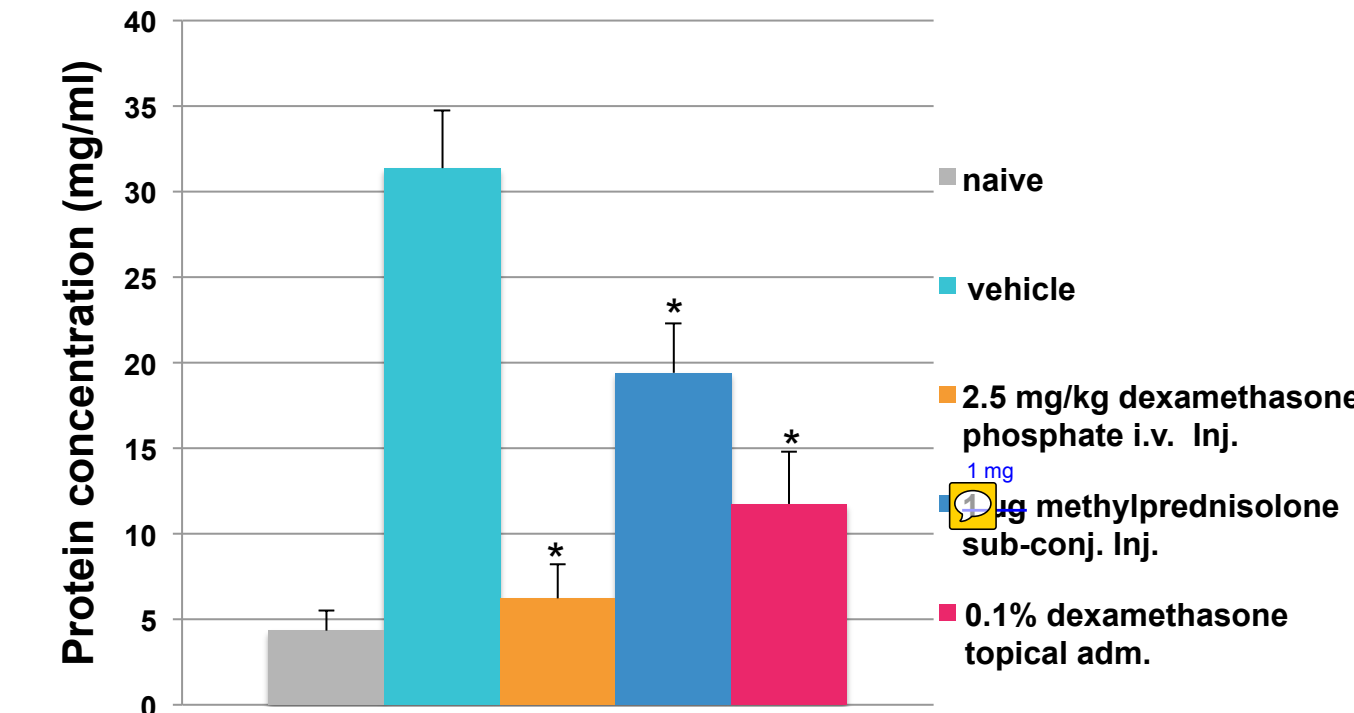


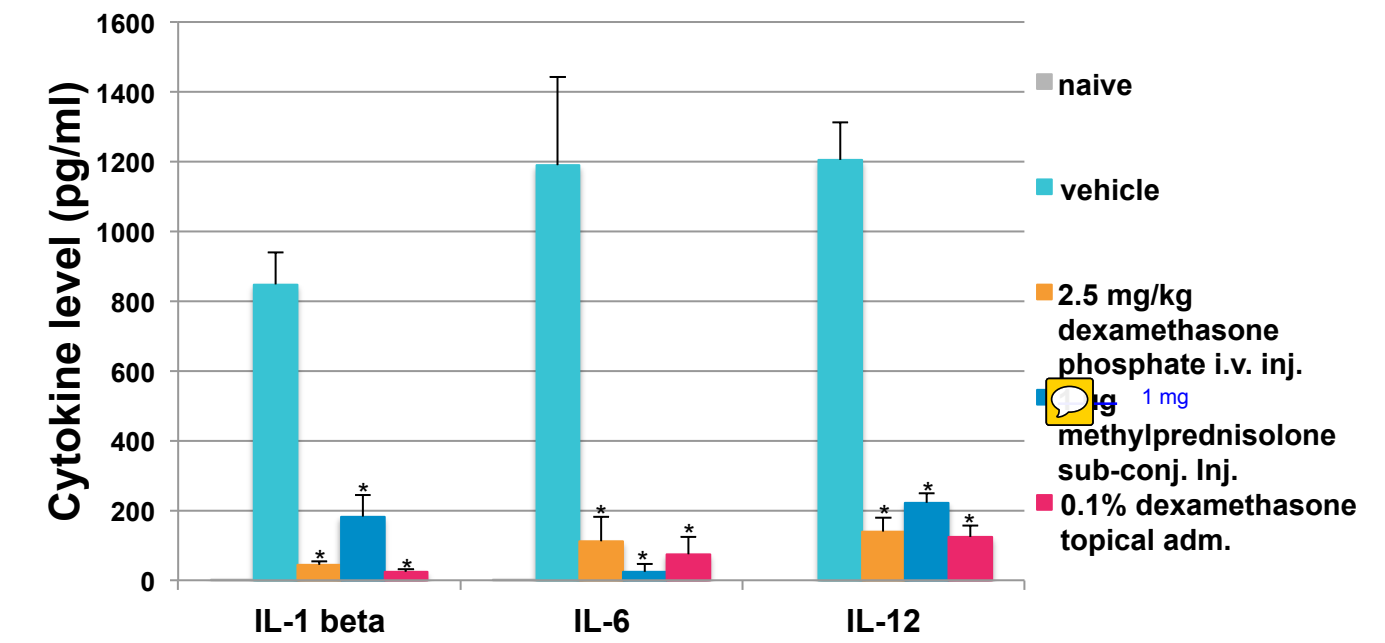
Figure 3 : Protein concentration in rat aqueous humor 24h after LPS induction.



Levels of IL-1  , IL-6, IL-12 in Aqueous Humor

In the groups treated with glucocorticoids the cytokine levels were at least four times and up to 48-fold lower than that for the untreated, LPS-induced group, depending on the cytokines observed and treatment.

Figure 4 : Cytokines levels in rat aqueous humor 24h after LPS induction



Conclusion

Both intravenous and topical administrations of dexamethasone markedly decreased clinical signs of EIU, inflammatory cell counts, protein concentration, and levels of IL-1 , IL-6 and IL-12 in aqueous humor. Sub-conjunctival administration of methylprednisolone also decreased the symptoms of EIU but to a lesser extent than the other two treatments.

Topical administration of dexamethasone allows for a therapeutic effect on the anterior segment of the eye in the rat EIU model and may present a viable alternative to systemic administration of glucocorticoids.

References

- Rosenbaum JT, M. H., Guss RB, Egbert PR. (1980). « Endotoxin-induced uveitis in rats as a model for human disease. » Nature 286(5773): 611-613.
- Planck SR, Huang XN, Robertson JE, Rosenbaum JT. (1994). « Cytokine mRNA levels in rat ocular tissues after systemic endotoxin treatment. » Invest Ophthalmol Vis Sci.35(3):924-930.
- De Vos AF, V. H. M., Verhagen C, Hoekzema R, Kijlstra A. (1995). « Systemic anti-tumor necrosis factor antibody treatment exacerbates endotoxin-induced uveitis in the rat. » Exp Eye Res 61(6): 667-675.