

# Effects of Dexamethasone in a Rat Model of Choroidal Neovascularization

L. Feraille, S. Grillo-Antonelli, N. Cimbolini, T. Caillaud, P.P. Elena  
Iris Pharma, La Gaude, France.



## Introduction :

Choroidal neovascularisation (CNV) is a major cause of severe central vision loss in patient with exudative age related macular degeneration (ARMD). In response to an increase of locally produced angiogenic factors, such as VEGF, vessels grow between Bruch's membrane and the RPE as well as into the subretinal space. Various strategies were developed, including eradication of CNV by laser photocoagulation, obstruction of CNV by photodynamic therapy (PDT), prevention of angiogenesis by treatment with steroids or anti VEGF agents. To demonstrate the success or failure of these therapeutic strategies, visualization and quantification of CNV are crucial. Although there are no direct animal models of ARMD, the rat laser trauma model was developed<sup>(1)(2)</sup>. The laser trauma induces fibrovascular proliferation (FVP) arising from the choroid.

## Purpose :

The aim of this study was to evaluate the efficacy of intravitreal, subconjunctival and oral administration of dexamethasone, and to demonstrate the success of this reference compound in a rat model of choroidal neovascularization.

## Methods :

### • Animals

Sixty (60) adult male Brown Norway rats were allocated in six groups.

### • Treatment/Administration

**Group1** = intravitreal injection (ivt) of 40µg dexamethasone phosphate in saline solution twice weekly in the right eye.

**Group2** = ivt of vehicle, saline solution, twice weekly in the right eye.

**Group3** = subconjunctival injection (subconj) of 120µg dexamethasone phosphate in saline solution twice weekly in the right eye.

**Group4** = subconj | injection of vehicle, saline solution, twice weekly in the right eye.

**Group5** = oral administration of 500µg/kg dexamethasone in olive oil daily.

**Group6** = oral administration of vehicle (olive oil) daily.

Treatment started the day of the laser injury and continued through Day 21.

### • Induction

All animal were anesthetized with intramuscular injection of 25 mg/kg ketamine and 5 mg/kg xylazine, and the pupils were dilated with tropicamide. With a contact lens, eight laser spots (150mW, 100ms, 75µm, Argon laser 532nm, Viridis) were applied to each right eye fundus in a circle around the optic disc

### • Fluorescein angiography (FA)

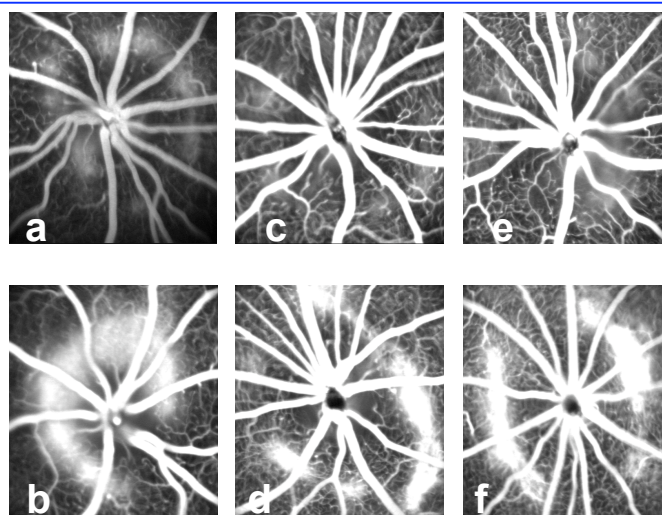
FA was performed on days 7, 14, 21 after the laser induction with Heidelberg Retinal Angiograph. Anesthetized animal received subcutaneous injection of Fluorescein Sodium (10%, 250µl/100g body weight. Photographies were taken in the late phase (10min). The intensity of fluorescein staining of each lesion was graded by two independent examiners using the leakage score (0 = no leakage to 3 = strong leakage) established by Takehana *et al*<sup>(3)</sup>.

### • Histology

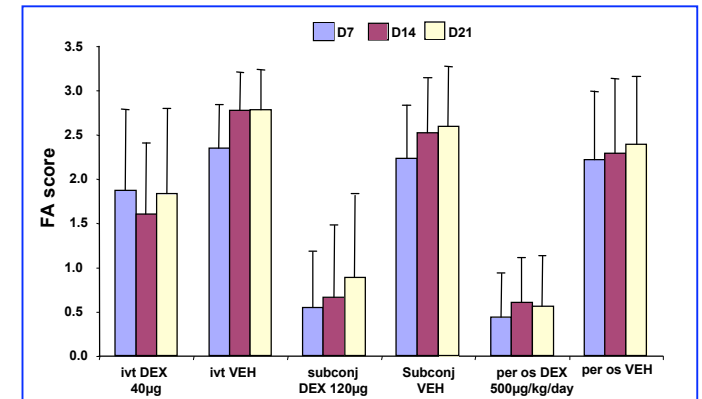
Twenty one days after the laser burn, the rats were euthanized with an overdose of sodium pentobarbital. Eyeballs were fixed in Bouin Hollande solution and embedded in paraffin. Six µm sagittal sections were performed and stained with hematoxylin and eosin.

## Result :

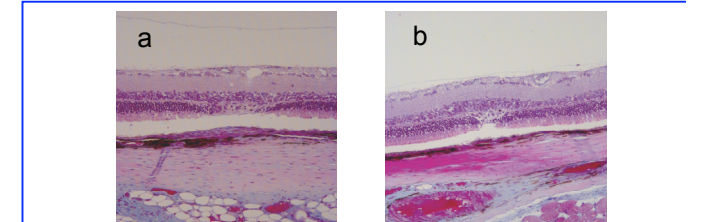
At day 21, compared to the vehicle groups, CNV lesions were reduced by 79% with oral administration of dexamethasone, by 65% with subconjunctival treatment and only by 33% with intravitreal administration.



**Figure 1 : Late phase fluorescein Angiograms (FA) carried out 21 days after the laser-induced rupture of the Bruch membrane.** Right eye received twice weekly 40µg dexamethasone (a), or vehicle (b) by intravitreal injection; 120µg dexamethasone (c), or vehicle (d) by subconjunctival injection; Rat were daily treated by oral gavage of 500 µg/kg dexamethasone (e) or vehicle (f).



**Graph 1 : Decreased of FA leakage in dexamethasone treated rats.** FA was performed on days 7, 14, 21 after the laser induction. The intensity of leakage in late phase FA were graded using the scale 0 = no leakage to 3 = strong leakage. Histograms represent the means + SD of scores per treatment and per time-point.



**Figure 2 : Light microscopy of retinal lesion 21 days after the laser-induced rupture of the Bruch membrane.** (a) typical section of control rat showing the marked membrane proliferation and thickening in subretinal space, (b) in treated rats (oral gavage of 500 µg/kg/day dexamethasone) the thickness of the lesion was decreased.

## Conclusions :

In our experimental condition, subconjunctival and oral administration of dexamethasone efficiently impaired CNV development. There was a trend indicating an inhibition of CNV with intravitreal injection of dexamethasone but not significant.

## References :

- (1)Tobe T, Takahashi K, Ohkuma H, Uyama M. Experimental choroidal neovascularization in the rat; Nippon Ganka Gakkai Zasshi. 1994 98(9):837- 45.
- (2)Dobi ET, Puliafito CA, Destro M. A new model of experimental choroidal neovascularization in the rat. Arch Ophthalmol. 1989 107(2):264-9.
- (3)Takehana Y, Kurokawa T, Kitamura T, Tsukahara Y, Akahane S, Kitazawa M, Yoshimura N. Suppression of laser-induced choroidal neovascularization by oral tranilast in the rat. Invest Ophthalmol Vis Sci. 1999 40(2):459-66.